

# Unicentric Castleman's Disease- A Case Report

Prashant Kumar Dontula<sup>1</sup>, Sumalatha Kasturi<sup>2</sup>, Praveen Kumar Manikyam<sup>3</sup>

<sup>1</sup> Surgical Oncologist  
Chalmeda Anand Rao  
Institute of Medical Sciences  
and Cancer Research Hospital  
Karimnagar, Telangana, India.

<sup>2</sup> Associate Professor  
Department of Pathology  
Chalmeda Anand Rao  
Institute of Medical Sciences  
Karimnagar, Telangana, India.

<sup>3</sup> General Surgeon  
Soumya Multi Speciality Hospital  
Karimnagar, Telangana, India.

## CORRESPONDENCE:

Dr. Sumalatha Kasturi  
DCH, MD(Path)  
Associate Professor  
Department of Pathology  
Chalmeda Anand Rao  
Institute of Medical Sciences  
Karimnagar - 505 001.  
Telangana, India.  
E-mail:  
sumalathakasturi97@gmail.com

## ABSTRACT:

Castleman's disease or angiofollicular lymph node hyperplasia is a rare clinicopathological entity characterised by benign proliferation of lymphoid tissue. Two clinical forms have been described. A unicentric presentation with the disease confined to a single anatomic lymph node which is more common and a multicentric presentation characterised by generalised lymphadenopathy and a more aggressive course.

Pathologically three histopathological subtypes have been described: Hyaline vascular type, plasma cell type and a mixed variant. Preoperative diagnosis of hyaline vascular type of Castleman's disease is difficult and the definitive diagnosis is based on the histopathological examination of post-operative pathological specimen. The definitive treatment of unicentric castleman's disease is complete surgical excision.

**Keywords:** Castleman's disease, unicentric, hyaline vascular.

## INTRODUCTION

Castleman's disease (CD) is an uncommon disorder characterised by angiofollicular lymph node hyperplasia related to the human herpes virus 8 (HHV-8) infection and the human immunodeficiency virus (HIV).<sup>[1]</sup> CD may be localised/unicentric or disseminated/multi-centric. Histologically three subtypes have been described: hyaline vascular type, plasma cell type or a mixed type.<sup>[2]</sup> Patients with localised hyaline vascular type are usually asymptomatic. The definitive diagnosis depends on postoperative pathological findings.

## CASE REPORT

A 34 year old female presented with slowly enlarging neck nodes since 4 months. No associated fever or cough. Her past medical and family history was non-specific. On examination non tender firm discrete mass was palpated below the right ear lobule. There was no

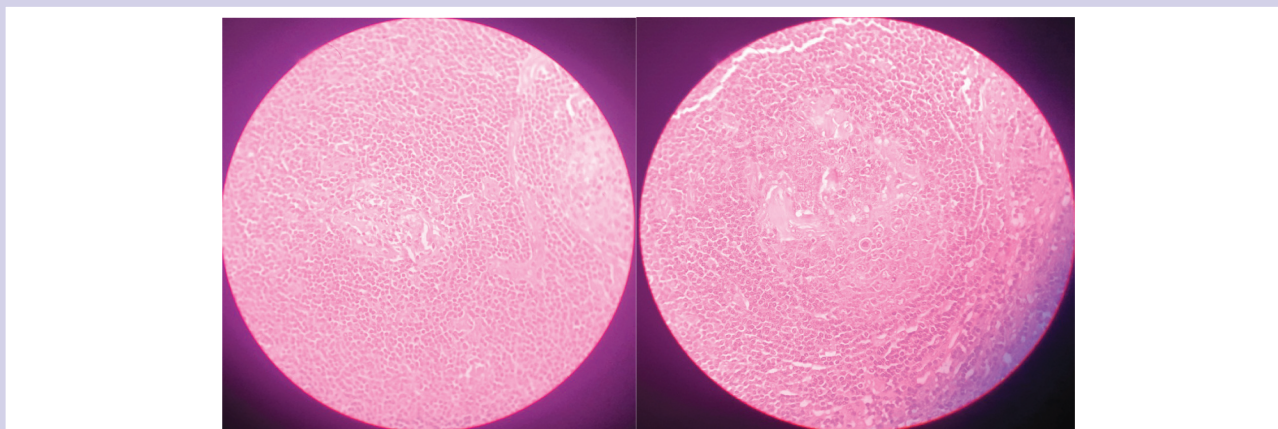
generalised lymphadenopathy or organomegaly. Routine blood investigations were normal. Ultrasound examination of the neck revealed a hypoechoic intraparotid lesion measuring 2.5x2 cm on the right side.

FNAC was performed and was suggestive of a lymphoproliferative disease. Excision was done and the tissue sent for histopathological examination which revealed hyaline vascular variant of unicentric castleman's disease.

Fig 1 and 2 are showing lymphocyte depleted hyalinised lymphoid follicles surrounded by lymphoid proliferation in onion skin pattern in the mantle zone.

## DISCUSSION

Castleman's disease was first described in 1956 by Benjamin Castleman, who identified a group of patients with solitary hyperplastic mediastinal lymph nodes with small germinal center resembling Hassall's corpuscles of



**Figure: 1 and 2 showing lymphocyte depleted hyalinised lymphoid follicles surrounded by lymphoid proliferation in onion skin pattern in the mantle zone.**

the thymus.<sup>[3]</sup> Clinically, CD has two forms: localised, described by Castleman, is more common. Multicentric with involvement of several sites, first described by Gaba et al. in 1972 is less common.<sup>[4]</sup>

Histologically the three main types are 1. Hyaline vascular type characterised by lymphoid follicular proliferation forming onion-skin pattern surrounding a hyalinised vessel at the centre of the follicle. 2. Plasma cell type characterised by sheets of mature plasma cells within interfollicular tissues. 3. Mixed variant MCD is a systemic disease characterised by fever, night sweats associated with generalised lymphadenopathy and hepato splenomegaly. Although the occurrence rate is unknown, it is frequently associated with HIV and HHV-8.<sup>[1]</sup>

UCD is the most common type and consists of localised lymphoid hyperplasia of young adults that is not associated with an HHV-8 infection and usually curable with surgical excision. The majority of patients are asymptomatic. Preoperative diagnosis of hyaline-vascular Castleman's disease is very difficult.

FNAC is usually non diagnostic and may be misdiagnosed as lymphoproliferative disease or reactive lymphoid hyperplasia. The definitive diagnosis is based on postoperative pathological findings. Once CD is diagnosed, MCD must be ruled out. Moreover, UCD may be associated with an increased risk of developing lymphoma, Hodgkin's and Non Hodgkin's lymphoma.<sup>[5]</sup>

The standard therapy for UCD hyaline vascular form of CD is surgical excision.<sup>[6]</sup> Surgery is curative when resection is complete, yielding a 5- year survival rate close to 100% with recurrences being infrequent.<sup>[7]</sup> Appropriate follow-up should be tailored to the specific CD variant and symptoms. Patients with unicentric disease without systemic involvement should have an additional

radiological assessment 6 to 12 months after initial therapy to verify recurrence.

## CONCLUSION

The aim of the case report is to emphasise the importance of histopathological examination to seal the diagnosis from other lymphoproliferative conditions.

## CONFLICT OF INTEREST :

The authors declared no conflict of interest.

## FUNDING : None

## REFERENCES

1. Naresh KN, Rice AJ, Bower M. Lymphnodes involved by multicentric castleman's disease among HIV-Positive individuals are often involved by Kaposi sarcoma. *Am J Surg Patho.* 2003; 32: 1006-1012.
2. Magrini U, Lucioni ML, Incardona P, Boveri E, Paulli M. Castleman's disease and update. *Pathologica.* 2003; 95(5):227-229.
3. Castleman B, Iverson L, Menezes VP. Localised mediastinal lymph node hyperplasia resembling thymoma. *Cancer.* 1956; 9: 822-830.
4. Gaba AR, Stein RS, Sweet DL, Variakojis D. Multicentric giant lymph node hyperplasia. *Am J Clin Pathol.* 1978; 69:86-90.
5. Larroche C, Cacoub P, Soulier J et al. Castleman's disease and lymphoma: report of eight cases in HIV negative patients and literature review. *Am J Haemat.* 2002; 69:119-126.
6. Robert H, Sgourdos G, Kritikos N, Didier D, Terraz S. Preoperative embolization of hypervascular Castleman's disease of the mediastinum. *Cardiovascular and interventional Radiol.* 2008; 31:186-188.
7. Shahidi H, Myers JL, Kvale PA. Castleman's disease. *Mayo Clinic Proceedings.* 1995; 70:969-977.